


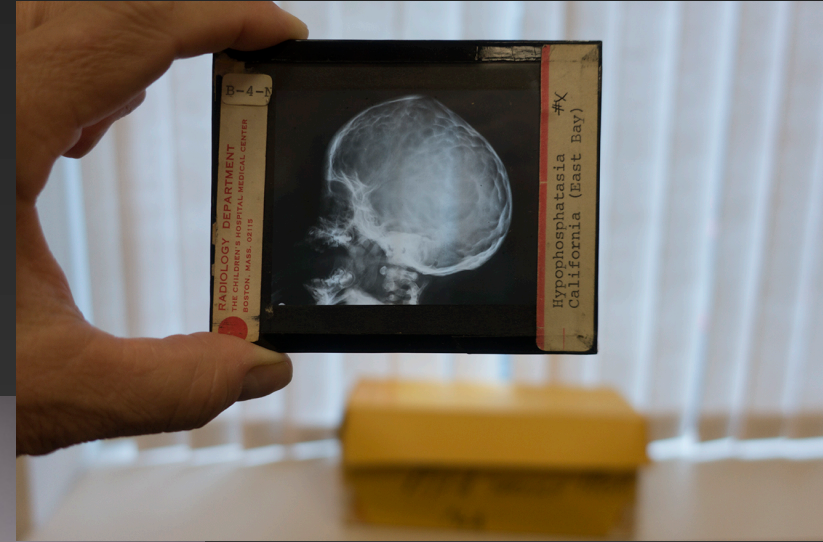
Radiology Education: Past, Present & Future

1950's-1960's




E.B.D. Neuhauser

1 talk/1 audience/5 lbs



1970's-1990's



JA Kirkpatrick

2-5 talks/1 audience/2 lbs.



1990's-2000's



GA Taylor

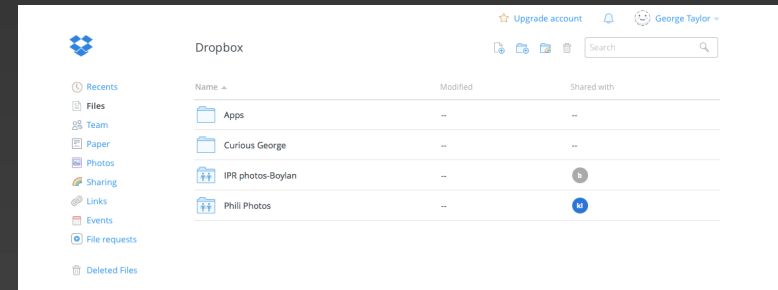
20 talks/ 1 audience/

20 gms + 2.4 lbs

(MAC)



2 TB flash drive



2016+

Live streaming



Google Hangouts

Messaging, Voice and Video Calls

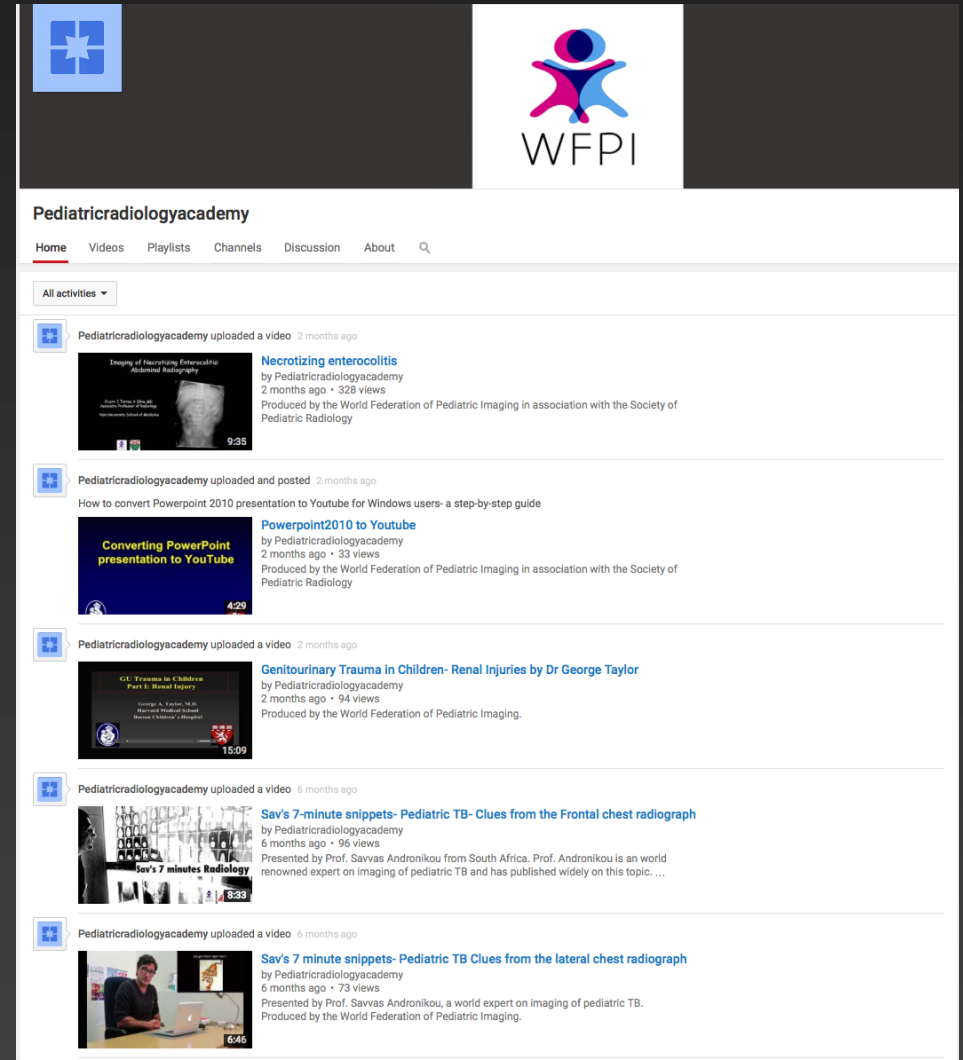


- ADOBE CONNECT

WFPI



The screenshot shows the WFPI website homepage. At the top left is the WFPI logo and the text "The World Federation of Pediatric Imaging". Navigation links include Home, ABOUT, EDUCATION, OUTREACH, CHILD IMAGING SAFETY, and Events. A search bar is located in the top right. The main content area features a large banner for "Thank Marilyn Goske Week" with a photo of Dr. Marilyn Goske and text celebrating her 8 years of leadership. Below this is a "CASE OF THE WEEK" section with a chest X-ray. Further down is a "VIDEO COMPETITION: IDoR 2015" section with a photo of a person at a computer and a "CLICK HERE" button. To the right is a "TWITTER" section showing a tweet from WFPI about a compact US imaging technology. Below the Twitter section is a "SMALL WORLD, WFPI's NEWSLETTER - MAY 2015" section with two newsletter preview images. At the bottom left, the text "OUR MISSION" is visible.

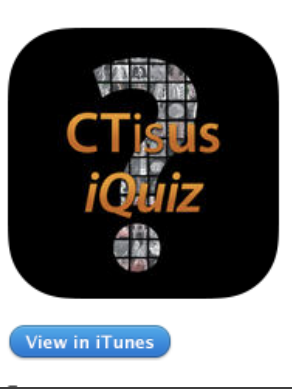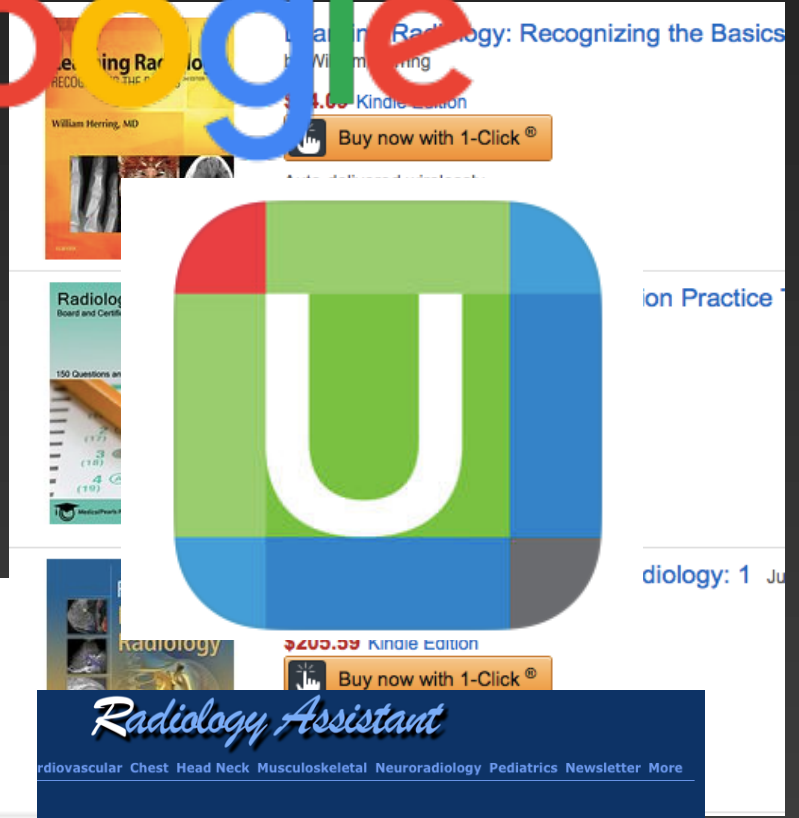



The screenshot shows the Pediatricradiologyacademy YouTube channel page. At the top is the channel logo and name. Below the navigation bar (Home, Videos, Playlists, Channels, Discussion, About) is a list of video uploads. The videos include: "Neerotizing enterocolitis" (2 months ago, 328 views), "Powerpoint2010 to Youtube" (2 months ago, 33 views), "Genitourinary Trauma in Children- Renal Injuries by Dr George Taylor" (2 months ago, 94 views), "Sav's 7-minute snippets- Pediatric TB- Clues from the Frontal chest radiograph" (6 months ago, 96 views), and "Sav's 7 minute snippets- Pediatric TB Clues from the lateral chest radiograph" (6 months ago, 73 views). Each video entry includes a thumbnail, title, uploader, date, view count, and a brief description.

12 months: 13 talks: 13,658 visits (since 4/15)

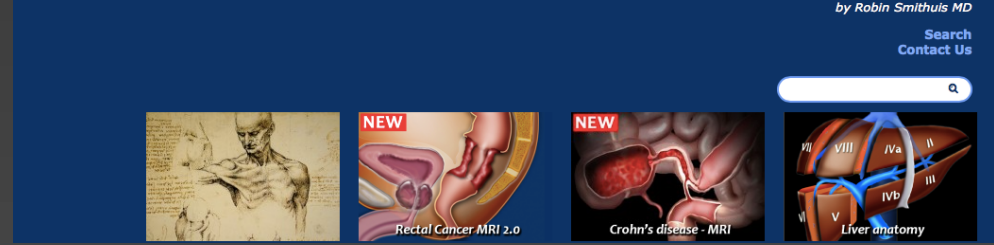
1950's-2000's

Google



Caffey 6 lbs (Amazon)

\$315



Trends

- Local Audience → Widespread, Distant Audience
- One-time → Enduring
- Hard-copy → Electronic
- One-size fits all → Customizable
- Long-interval updates → Short interval (continuous) updates

2016+: Where Should we go??

- Shorter, focused content
- Based on adult learning
- Relevant to broad range of environments
- Curated
- Current
- Several languages
- Easily accessible (web-based)

Initial Strategy/ What are we looking for?

- 1. Develop high-quality, relevant and accessible content**
- 2. All areas of Pediatric Radiology/Imaging**
- 3. Keynote / Powerpoint presentations, 10 to 15 minutes in duration**
- 4. Basic to Advanced**
- 5. Resource rich and poor environments**
- 6. English y Español (inicialmente, otros a seguir)**

2016+: How do we get there??

- Consider full engagement and support for web-based educational content
 - WFPI
 - E-book self-publication
 - Sanjay

